Deformable image registration of diagnostical CT and planning CT for breast conserving radiotherapy

Xin Xie[1], Hui Yan[1], Jianrong Dai[1]

1Department of Radiation Oncology, National Cancer Center/National Clinical Research Center for Cancer/Cancer Hospital, Chinese Academy of Medical Sciences and Peking Union Medical College, Beijing, China

JULY 12–16 2020 VIRTUAL
JOINT AAPM | COMP MEETING
EASTERN TIME [GMT-4]

INTRODUCTION

- Deformable image registration (DIR) can add value in accurate delineation of breast tumor bed and its target volume for breast conserving radiotherapy, with
  - Diagnostical CT image acquired before surgery;
  - Planning CT image acquired after surgery.
- However, this can be challenging due to large deformation and non-correspondence caused by tumor resection and clip insertion.
- So far there is no report on feature-based DIR method in this field due to difficulty in identifying landmarks in clinical practice. For intensity-based DIR method, there are several applications (1-3). However, certain issues have to be considered which usually don't exist in conventional registration applications (4).

AIM

- Develop an improved B-Splines based DIR method to register CT images before and after breast conserving surgery for higher registration accuracy.
- This method should be feasible for target volume definition in treatment planning of postoperative breast cancer radiotherapy.

METHOD

- The registration is performed by two steps using Elastix (5):
  - Affine transformation, is used for initial alignment;
  - B-Splines based DIR method improved with the introduction of point metric and masking technique, is used to refine the initial alignment.
- The point metric (6) minimizes the distance between two point sets with known correspondence. The masking technique excludes nonsense grey values since areas outside the mask do not actively contribute to the cost function.

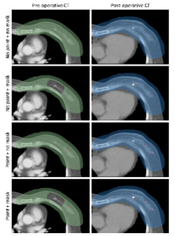

Figure 1 The illustrations of four combinations of the point metric and masking technique. The green label represents the fixed image mask (if not subtracting tumor expansion, it means no mask) and blue label represents the moving image mask (if not subtracting postoperative changes, it means no mask). Point pairs for calculating point metric are labeled in red dots. The corresponding point sets in each patient contain average 30 pairs of points located in unaffected breast tissue and marked manually by physician.

RESULTS

The running time of a single test including affine and B-Splines based registration is averagely 150 seconds. With application of point metric and masking technique, the running time is less changed.

The statistics of TRE for five different methods are shown in Table 1. Among different B-Splines based DIR methods listed in Table 1, the application of point metric (DIR-3 and DIR-4 in Table 1) significantly improves the soft tissue alignment. In the evaluation of rigid structure and boundary, all DIR methods approach the clinical tolerance of 2-3mm (4). The application of point metric and masking technique shows higher accuracy in registration of soft tissue, but less accuracy in registration of boundary and rigid structure.

Representative transverse views of the spatial Jacobian map around the tumor area are shown in Figure 2. The determinant of the Jacobian of the deformation is positive for all patients. Without the application of masking technique (as shown in Fig. 2A and Fig. 2C), there exists local expansion of volume near the 2-cm expansion of tumor. It seems unrealistic because the 2-cm expansion is approximate to the real surgical margin of tumor.

The Image overlay displays and the Checkerboard images between the fixed and the transformed moving images are shown in Figure 3. For qualitative visualization, the region next to tumor can be more reliable in assessing the accuracy. Therefore in our study unaffected soft tissue are inspected more carefully. Visual assessment of DIR methods is better than that of affine transformation. And the method with point metric achieves better matching for soft tissue, regardless of the application of masking technique.

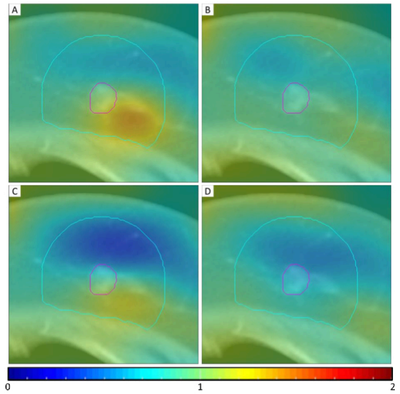

Figure 2 The transverse views of the spatial Jacobian map of the transformation for A) DIR method without point metric and masking technique; B) DIR method without point metric and with masking technique; C) DIR method with point metric and without masking technique; D) DIR method with point metric and masking technique. Values greater than 1 (red end of spectrum) indicate local volume expansion. Values less than 1 (blue end of spectrum) indicate volume reduction. The pink contour represents original tumor and the blue contour represents its expansion with 2cm margin.

Table 1 The results of TRE (mm) for AT and DIR methods. The columns showed the statistics (mean, max) corresponding to three categories of point sets (boundary, rigid structure, and soft tissue).
AT is affine transformation only; DIR-1 is DIR method without point metric and masking technique; DIR-2 is DIR method without point metric and with masking technique; DIR-3 is DIR method with point metric and without masking technique; DIR-4 is DIR method with point metric and masking technique.

	Mean	Max	Mean	Max	Mean	Max
AT	9.50±4.51	20.74	8.92±7.76	30.38	8.26±4.05	16.88
DIR-1	5.65±5.22	20.45	3.38±3.55	14.47	6.86±4.48	17.53
DIR-2	5.43±5.35	20.63	3.34±3.49	14.34	6.64±4.21	17.46
DIR-3	3.33±1.63	6.98	3.55±3.84	15.69	2.47±0.74	4.07
DIR-4	3.50±1.88	7.46	3.61±3.92	15.88	2.39±0.56	3.56

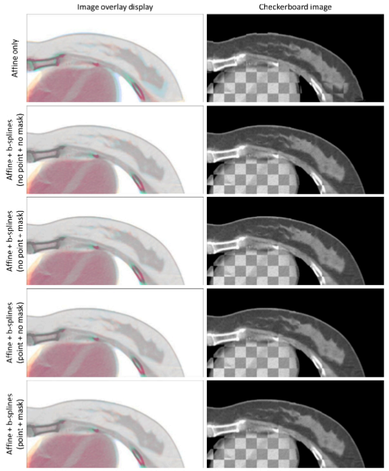

Figure 3 Image overlay displays and Checkerboard images for visual assessment. It is noteworthy to compare the visualization with Table 1.

CONCLUSIONS

- Efficiently and effectively register CT images before and after breast conserving surgery;
- With the application of point metric and masking technique to intensity-based B-Splines DIR method, the influence of large deformation and non-correspondence on registration accuracy of DIR method could be reduced to certain degree;
- With the improved DIR method, the tumor bed and its target volume can be delineated from postoperative CT image more accurately and reliably for breast cancer radiotherapy.

ACKNOWLEDGEMENTS

Funding: This work is partially supported by National Natural Science Foundation of China (11875320) and Beijing Hope Run Special Fund of Cancer Foundation of China (LC2018A08).

REFERENCES

1. **Kirova YM et al**. Use of deformable image fusion to allow better definition of tumor bed boost volume after oncoplastic breast surgery. *Surgical oncology. 2011;20(2):e123-5*

2. **Hilts M et al**. Deformable image registration for defining the postimplant seroma in permanent breast seed implant brachytherapy. *Brachytherapy. 2015;14(3):409-18*

3. **Wodzinski M et al**. Improving oncoplastic breast tumor bed localization for radiotherapy planning using image registration algorithms. *Physics in medicine and biology. 2018;63(3):035024*

4. **Brock KK et al**. Use of image registration and fusion algorithms and techniques in radiotherapy: Report of the AAPM Radiation Therapy Committee Task Group No. 132. *Medical physics. 2017;44(7):e43-e76*

5. **Klein S et al**. elastix: a toolbox for intensity-based medical image registration. *IEEE transactions on medical imaging. 2010;29(1):196-205*

6. **Baiker M et al**. Automated registration of whole-body follow-up MicroCT data of mice. *Medical image computing and computer-assisted intervention : MICCAI International Conference on Medical Image Computing and Computer-Assisted Intervention. 2011;14(Pt 2):516-23*

CONTACT INFORMATION

Contact: Xin Xie: xiexin_crayon@163.com